

Two at one blow: reemergence of tularemia in Upper Austria

Sonja Lang, Michael Kleines

¹Sektion für Virologie, Department für Hygiene, Mikrobiologie und Sozialmedizin,
Medizinische Universität Innsbruck, Innsbruck, Austria

SUMMARY

After field dressing a rabbit in the state of Upper Austria, Austria two members of a family were infected with tularemia in November 2010. The patients were a man in his forties and his father-in-law in his sixties. Tularemia is a rare disease in Austria. In the last 10 years between 2 and 8 cases have been reported annually. Of the total of 40 cases none was reported in the state of Upper Austria. Thus, this case report documents the reemergence of tularemia in Upper Austria.

Key words: Tularemia, *Francisella tularensis*, Upper Austria, Zoonotic disease, Lymphadenitis.

Received February 02, 2012

Accepted May 18, 2012

INTRODUCTION

Tularemia is a rare zoonotic, notifiable disease in Austria. Annually, two to eight cases have been reported since 2002 (Bundesministerium für Gesundheit, 2012). The infection is caused by the facultative intracellular, gram-negative bacterium *Francisella tularensis* (Weber *et al.*, 2009). Many small mammals, especially rodents, serve as natural reservoir for the pathogen (Keim *et al.*, 2007). It is transmitted from animals to humans by consumption of contaminated water and aliments, by contact with infected animal tissue, or through the inhalation of infective aerosol. Even transmission through tick bites is possible. The clinical manifestation of the disease varies depending on:

1. path of infection;
2. virulence and dose of the pathogen;
3. immune status of the recipient.

The incubation period is typically 3-6 days (Ellis

et al., 2002). In most instances clinical signs commence with abrupt fever, headache, lymphadenitis, fatigue, and skin lesions. Less common are conjunctivitis, pharyngeal ulcer, diarrhea, pneumonia, pericarditis, and sepsis. Severe cases are mainly caused by *Francisella tularensis ssp. tularensis*, milder disease by *Francisella tularensis ssp. holarctica* (Zanger *et al.*, 2010; Foley *et al.*, 2010).

In the past ten years, the large majority of the cases in Austria (37/40) were registered in the states of Lower Austria, Burgenland, Vienna, and Styria (Figure 1). None was reported in the state of Upper Austria. We present two familial cases from Upper Austria, a non-endemic area, following field dressing a rabbit. The patients were a man in his forties (patient 1) and his father-in-law in his sixties (patient 2).

CASE REPORT

In mid November 2010 the two patients went hunting in the municipal area of Pilsbach near Vöcklabruck (Upper Austria). Patient 2 shot a hare. The next day both skinned and field dressed the rabbit and in so doing Patient 2 cut his right forefinger.

Corresponding author

Michael Kleines

Sektion für Virologie

Department für Hygiene und medizinische Mikrobiologie

Medizinische Universität Innsbruck

Fritz-Pregl-Straße 3, A-6020 Innsbruck, Austria

E-mail: michael.kleines@i-med.ac.at

Patient 1

Patient 1 developed fever (max 38.5°C) and a mild headache three days after field dressing of the hare. He went to his family doctor who prescribed painkillers and signed him off work. Five days later his condition deteriorated. His skin featured small purulent blisters. Patient 1 consulted the doctor again. Blood analysis revealed elevated inflammatory markers (C-reactive protein: 18,4 mg/l, blood sedimentation 30 mm/h). A follow-up-examination was agreed upon, but the patient did not show up.

Over the course of the following weeks the patient suffered from increasing dragging pain from his left hand to his left axilla until he was no longer able to lift his left arm. A bulge in his left armpit was detected. Ultrasound examination revealed an abscess (Figure 2) and the patient was admitted to the hospital in Vöcklabruck for surgical intervention.

On the 20th January 2011, the suspicious tissue was removed and histological findings led to the diagnosis of abscess/phlegmon. Abdominal ultrasound was unsuspecting and the patient was dismissed after 4 days.

Serology for tularemia was initiated at the beginning of February 2011 and revealed a titer of 1:640 using a hemagglutination assay (BD, Franklin Lakes, New Jersey, USA; titers of 1:160 and more are strongly suggestive for infection). Treatment consisted of 200 mg doxycycline daily for twenty days. 10 days after the first blood sample was taken, a follow-up blood analysis showed an increase of titer to 1: 2560.

Patient 2

Two days after field dressing of the hare patient 2 developed fever of 38-39°C and his injured right forefinger swelled and ailed increasingly despite using ammonium bituminosulfonate (Ichtholan, Ichthyol-Gesellschaft Cordes, Hamburg, Germany). No suppurative blisters appeared. After another few days he suffered from increasing dragging pain and swelling in his right axilla. His family doctor prescribed amoxicillin/clavulanic acid (Xiclav, G.L. Pharma GmbH, Lannach, Austria) for seven days. Swelling and pain in the right finger and axilla declined, but the patient still felt weak. About two weeks after the injury, fever returned and

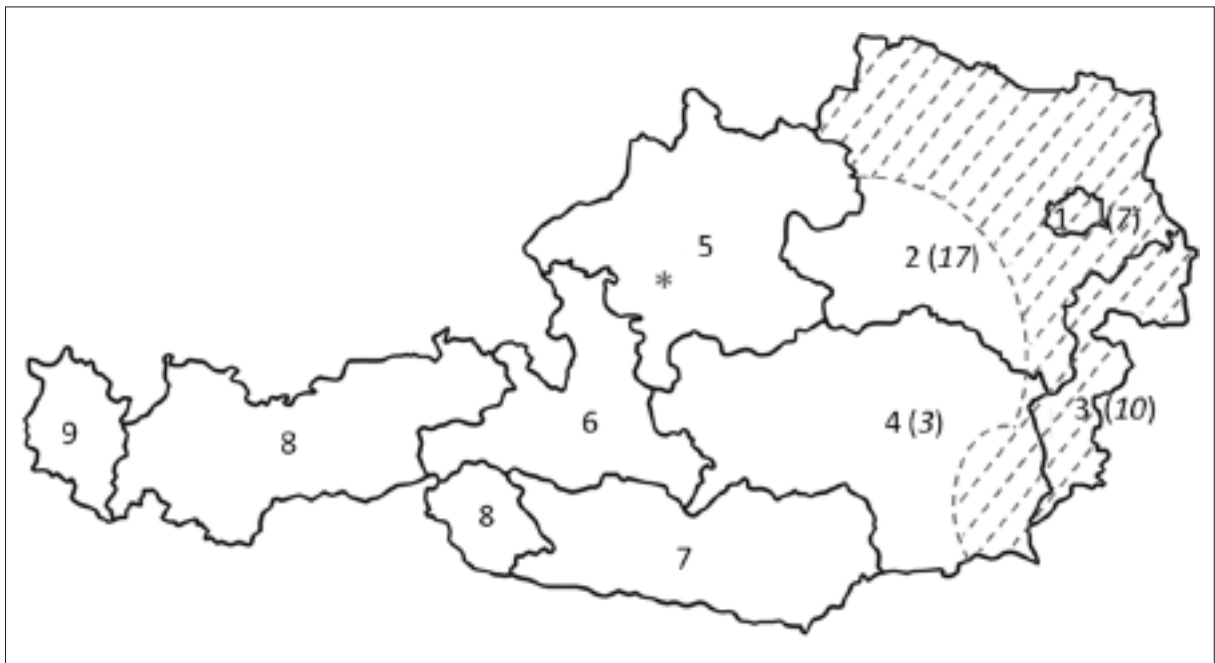


FIGURE 1 - Areas of Austria with endemic tularemia cases. solid lines: borders of Austria and the Austrian states; broken lines: tularemia endemic areas; *: Pilsbach/Upper Austria; 1: Vienna; 2: Lower Austria; 3: Burgenland; 4: Styria; 5: Upper Austria; 6: Salzburg; 7: Carinthia; 8: Tyrol; 9: Vorarlberg; numbers in brackets: human tularemia cases from 2002 to 2011 in states with endemic tularemia.

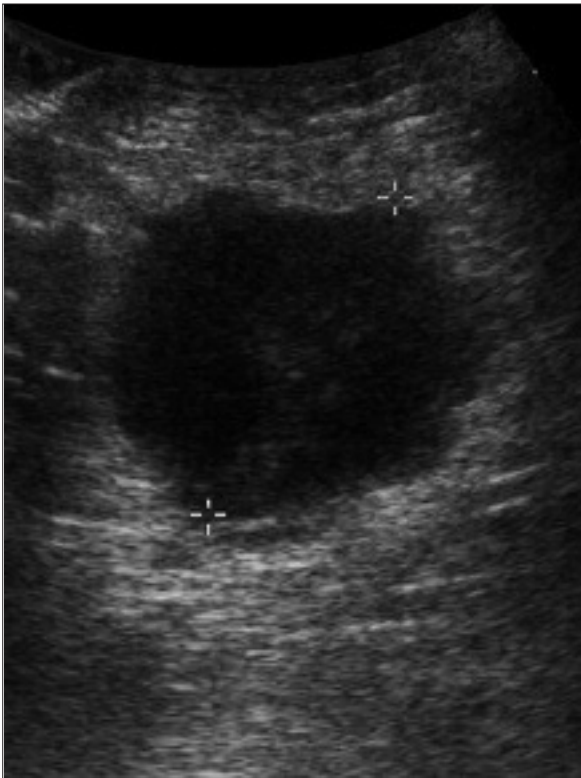


FIGURE 2 - Ultrasound of the left axilla (patient 1): circumscribed fluid accumulation with a diameter of circa 4, 3 cm (special thanks to Dr. F. Seifert, Vöcklabruck).

the patient went to the outpatient clinic of the local hospital. Ambulant laboratory investigations depicted minimal increased inflammatory markers, chest x-ray was normal.

The patient received painkillers, gastric protection and left the hospital. But the general state of health remained poor for another three weeks.

Being aware of the infection of his son-in-law, he visited his family doctor again at the beginning of March 2011. Serology for tularemia showed a titer of 1:1280. 200 mg of doxycycline daily was administered for 15 days. A follow-up blood analysis at the end of March resulted in an antibody titer decrease to 1:640.

DISCUSSION

Gold standard for diagnosis of infections with *Francisella tularensis* is culture of the bacterium. However, the pathogen is difficult to grow and

serious, even fatal, laboratory infections have been reported. Therefore, serology is used for diagnosis in the routine laboratory setting. Besides hemagglutination assays as used by us, ELISA formats analyzing total antibodies as well as IgG- and IgM-specific formats are available for antibody detection.

The cellular immune response can be determined using a lymphocyte stimulation test (Eliasson *et al.*, 2008). For early or very sensitive diagnosis PCR assays are available (Hepburn *et al.*, 2008).

Drugs of first choice for treatment of more severe cases of tularemia are aminoglycosides like gentamicin or streptomycin, given for at least 10 days (WHO, 2007; Dennis *et al.*, 2001). Disadvantages of these agents are oto- /nephrotoxicity and the parenteral administration (Tärnvik *et al.*, 2007). In milder cases doxycycline or quinolones are further therapeutic options (WHO, 2007). Both can be administered orally. Drawback of doxycycline is the bacteriostatic effect accompanied by relapses especially if the duration of therapy is too short (Tärnvik *et al.*, 2007; Enderlin *et al.*, 1994).

Therefore doxycycline therapy for at least 15 days is recommended (WHO, 2007). Quinolones, especially ciprofloxacin, offer a good alternative for oral treatment of tularemia. Duration of therapy should be continued for 10-14 days. They exhibit a bactericidal effect, are less toxic than aminoglycosides, and they can be used for treatment of tularemia in children (Tärnvik *et al.*, 2007; WHO, 2007; Dennis *et al.*, 2001; Johansson *et al.*, 2000). Beta-lactam-antibiotics are ineffective on *Francisella tularensis*.

A key parameter for explanation of the distribution of the *Francisella tularensis* in Austria is the climate. *Francisella tularensis* is distributed in areas of Austria with warm winters, low may temperatures, and wet summers which favor the dissemination of the pathogen in the hare population (Deutz *et al.*, 2009). However, the human tularemia cases described by us were outside of both, (1) the areas in east of Austria, southeast of Austria, and at the border region of the states of Upper Austria and Lower Austria, which were predicted to facilitate dissemination of the pathogen based on climate data, as well as (2) the almost identical areas with regular notification of human tularemia.

CONCLUSIONS

Our cases emerged in an Austrian state in which the disease had not been notified for 10 years. The time delay between tularemia-associated symptoms and the correct diagnosis as well as effective therapy was about 3 months. Clinicians should be aware of this polymorphous disease and keep tularemia in their minds for differential diagnosis of febrile illnesses and lymphadenitis in such a way that correct diagnostics and therapy can be initiated in good time. In the course of global warming the area with optimal climate for dissemination of *Francisella tularensis* may increase in Austria by factor 3 in the next decades (Deutz *et al.*, 2009). Thus, the number of cases of human tularemia may increase in areas of Austria and other countries that are presently regarded as non-endemic.

ACKNOWLEDGMENTS

The authors thank the patients involved and their physicians Dr. B. Panhofer, Dr. C. Urbanek, and Dr. F. Seifert for their cooperation.

REFERENCES

- BUNDESMINISTERIUM FÜR GESUNDHEIT. Jahresstatistik meldepflichtiger Infektionserkrankungen ab 2000. [cited 2012 Feb 01] Available from: http://www.bmg.gv.at/home/Schwerpunkte/Krankheiten/Uebertragbare_Krankheiten/StatistikeS/Jahresstatistik_meldepflichtiger_Infektionskrankheiten_ab_2000.
- DENNIS D.T., INGLESBY T.V., HENDERSON D.A., BARTLETT J.G., ASCHER M.S., EITZEN E., FINE A.D., FRIEDLANDER A.M., HAUER J., LAYTON M., LILLIBRIDGE S.R., MCDADE J.E., OSTERHOLM M.T., O'TOOLE T., PARKER G., PERL T.M., RUSSELL P.K., TONAT K., WORKING GROUP ON CIVILIAN BIODEFENSE. (2001). Tularemia as a biological weapon. Medical and Public Health Management. *JAMA* **285**, 2763-2773.
- DEUTZ A., GUGGENBERGER T., GASTEINER J., STEINECK T., BAGO Z., HOFER E., AUER I., BÖHM R. (2009). Untersuchungen zur Verbreitung der Tularämie in Österreich unter dem Aspekt des Klimawandels. *Vet. Med. Austria*. **96**, 107-113.
- ELIASSON H., OLCEN P., SJÖSTEDT A., JURSTRAND M., BÄCK, E., ANDERSSON S. (2008). Kinetics of the immune response associated with tularemia: comparison of an enzyme-linked immunosorbent assay, a tube agglutination test, and a novel whole-blood lymphocyte stimulation test. *Clin. Vaccine Immunol.* **15**, 1238-1243.
- ELLIS J., OYSTON P.C.F., GREEN M., TITBALL R.W. (2002). Tularemia. *Clin. Microbiol. Ref.* **15**, 631-646.
- ENDERLIN G., MORALES L., JACOBS R.F., CROSS, J.T. (1994). Streptomycin and alternative agents for the treatment of tularemia: review of the literature. *Clin. Infect. Dis.* **19**, 42-47.
- FOLEY J.E., NIETO N.C. (2010). Tularemia. *Vet. Microbio.* **140**, 332-338.
- HEPBURN M.J., SIMPSON A.J.H. (2008). Tularemia: current diagnosis and treatment options. *Expert Rev. Anti Infect. Ther.* **6**, 231-240.
- JOHANSSON A., BERGLUND L., GOTHEFORS L., SJÖSTEDT A., TÄRNVIK A. (2000). Ciprofloxacin for treatment of tularemia in children. *Pediatr. Infect. Dis. J.* **19**, 449-453.
- KEIM P., JOHANSSON A., WAGNER D.M. (2007). Molecular epidemiology, evolution, and ecology of *Francisella*. *Ann. N.Y. Acad. Sci.* **1105**, 30-66.
- TÄRNVIK A., CHU M.C. (2007). New approaches to diagnosis and therapy of tularemia. *Ann. N. Y. Acad. Sci.* **1105**, 378-404.
- SONNTAG H. (2012). Lexikon der Infektionskrankheiten des Menschen. 4th ed. Heidelberg, Springer MedizinVerlag, Emerging and Re-emerging Infectious diseases. *Francisellatularensis*. 313-316.
- WHO (2007). WHO Guidelines on Tularaemia. [cited 2012 Feb 01] Available from: http://www.who.int/csr/resources/publications/WHO_CDS_EPR_2007_7.pdf
- ZANGER P., KNOBLOCH J. (2010). Infektionskrankheiten der Haut. 3rd ed. Stuttgart, Georg ThiemeVerlag KG, Chapter 25.8, Tularämie, 286-290.